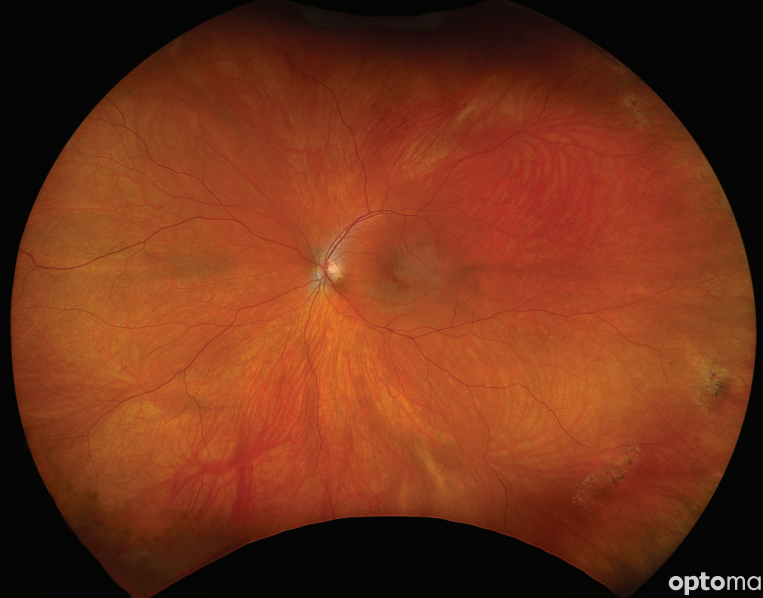
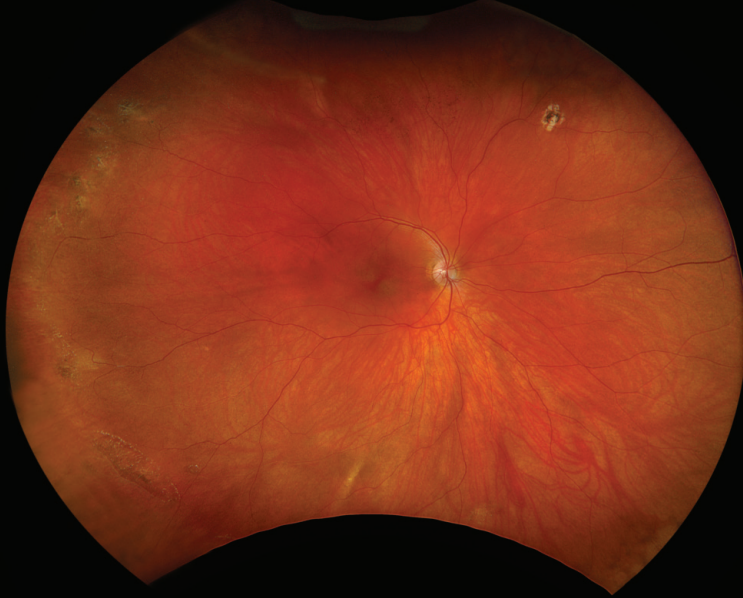
optomap[®]

HAS EXCELLENT AGREEMENT WITH EXAM FOR PERIPHERAL LESIONS



optomap[®]

optomap is a clinically useful multimodal tool for the assessment of eyes with peripheral retinal lesions, with a high sensitivity and reproducibility.¹

- **optomap** has a sensitivity of 89% for peripheral retinal lesions when compared to indirect ophthalmoscopy.¹
- 64% of patients have peripheral abnormalities such as drusen, peripheral degeneration and pigmentation visualized with **optomap**, which provide insight into biomarkers for disease.²
- 70% of patients with lattice degeneration have vitreoretinal traction observed on Optos[®] *Silverstone SS-OCT* not evident on clinical exam.³
- 50% of eyes with a retinal hole had traction seen on *Silverstone SS-OCT* not evident on clinical exam.³
- **optomap** is a non-mydratric, non-invasive, high-resolution image captured in 0.5 seconds that supports the identification of peripheral lesions, including retinal holes in patients uncooperative for peripheral fundus screening or with deep-set eyes.³
- **optomap** is valuable in the diagnosis and treatment of ocular disorders, including retinal vascular diseases, retinal and choroidal dystrophies and retinal inflammatory disorders as well as systemic diseases.⁴

“[Optos] multimodal approach has proven invaluable in detecting subtle changes in the retina, often undetectable through standard clinical examination, enabling early intervention and potentially improving patient outcomes. This new imaging technology also serves as a valuable tool for patient education, teaching trainees, and documentation for medicolegal purposes.”

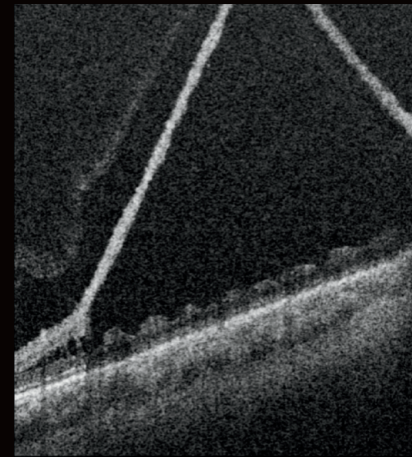
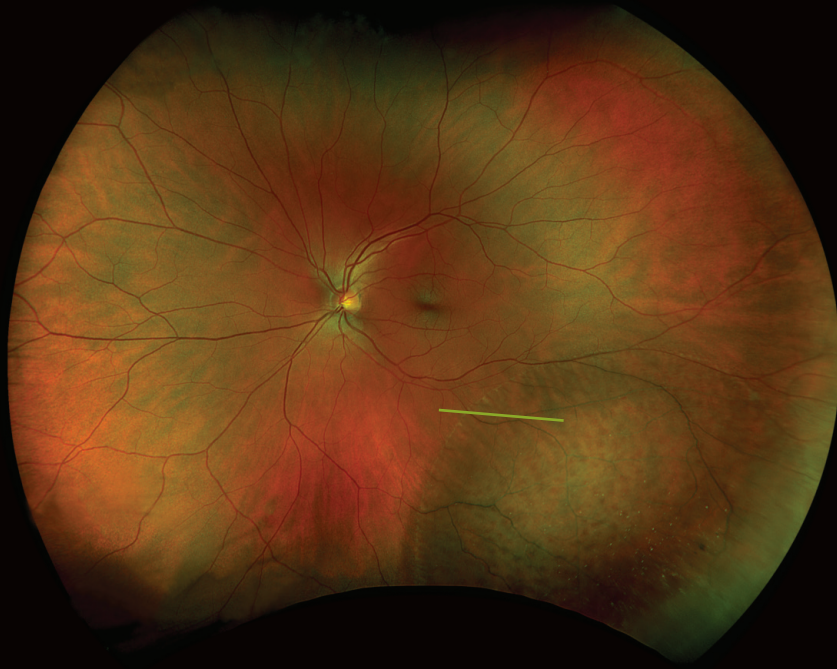- Saudi Journal of Ophthalmology, 2024

See how **optomap** will help you manage your patients. For more information call **800-854-3039** or **BDS@optos.com**.



CLINICAL SUMMARY

optomap has excellent agreement with exam for peripheral lesions



optomap

optomap *rg* and navigated *SS-OCT* of retinoschisis inferotemporally captured on *Silverstone*

- 99% of the time, high-quality and medically meaningful images of the peripheral retina and vitreoretinal interface are obtainable with Optos *Silverstone* revealing vitreous floaters and opacities, posterior vitreous detachment, retinal hole and tears, pigmented lesions and peripheral retinal degeneration.⁵
- Optos *Silverstone* helps visualize findings multimodally with simultaneous fundus, ultra-widefield fluorescein angiography, indocyanine green angiography and navigated peripheral *SS-OCT*, which can change the clinical assessment and management of retinal and choroidal vasculopathies.⁵
- **optomap** provides a four-channel image review with a green-separated channel that adds detail of the neurosensory retina, particularly helpful in denoting the presence of subtle retinoschisis, aiding in differential diagnosis from retinal detachment and informing management decision.⁶
- Optos *Advance*TM review software enhances visualization of findings by allowing manual magnification and adjustment of images as well as rotation of volume scans to aid image interpretation and improve diagnostic and therapeutic options.⁵

References:

1. Comparison Between Ultra-Widefield Pseudocolor Imaging and Indirect Ophthalmoscopy in the Detection of Peripheral Retinal Lesions. *Ophthalmic Surgery, Lasers, & Imaging Retina*. 2019 2. Sharma, Pariipoorna et al. "Prevalence of peripheral retinal findings in retinal patients using ultra-widefield pseudocolor fundus imaging." *Scientific reports* vol. 13,1 20515. 22 Nov. 2023. doi:10.1038/s41598-023-47761-x 3. Agarwal, Ayushi et al. "Evaluation of peripheral retinal degenerations using ultra-widefield swept source optical coherence tomography." *Graefes archive for clinical and experimental ophthalmology*. 23 Sep. 2024. doi:10.1007/s00417-024-06593-9 4. Nagiel, Aaron et al. "ULTRA-WIDEFIELD FUNDUS IMAGING: A Review of Clinical Applications and Future Trends." *Retina* (Philadelphia, Pa.) vol. 36,4 (2016): 660-78. doi:10.1097/IAE.0000000000000937 5. Stanga, Paulo E et al. "The role of ultra-widefield imaging with navigated central and peripheral cross-sectional and three-dimensional swept source optical coherence tomography in ophthalmology: Clinical applications." *Saudi journal of ophthalmology : official journal of the Saudi Ophthalmological Society* vol. 38,2 101-111. 23 Apr. 2024. doi:10.4103/sjopt.sjopt_59_24 6. Orr, Samantha et al. "Novel features of degenerative retinoschisis identified using ultra-widefield multicolor channels: A review of 139 eyes." *Acta ophthalmologica* vol. 102,6 (2024): e961-e969. doi:10.1111/aos.16683



Optos UK/Europe
+44 (0)1383 843350
ics@optos.com

Optos North America
800 854 3039
usinfo@optos.com

Optos DACH
DE: 0800 72 36 805
AT: 0800 24 48 86
CH: 0800 55 87 39
ics@optos.com

Optos Australia
+618 8444 6500
auinfo@optos.com

