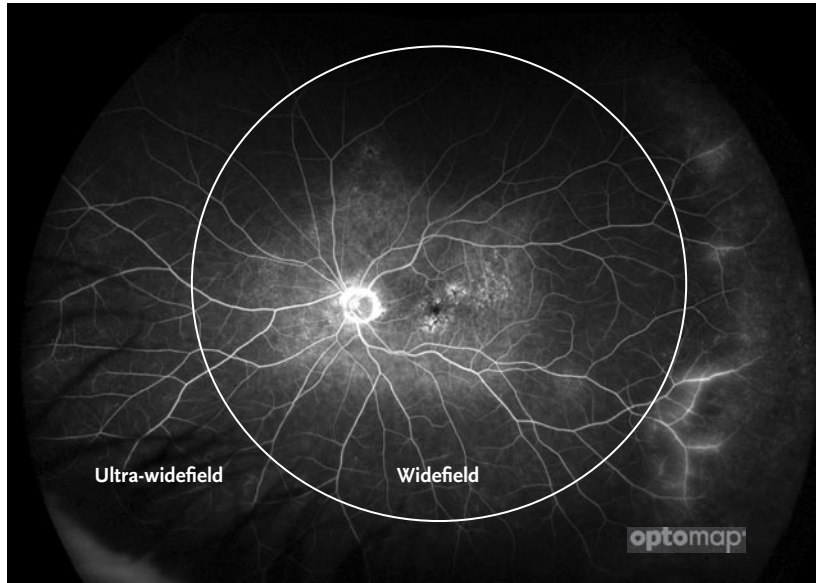
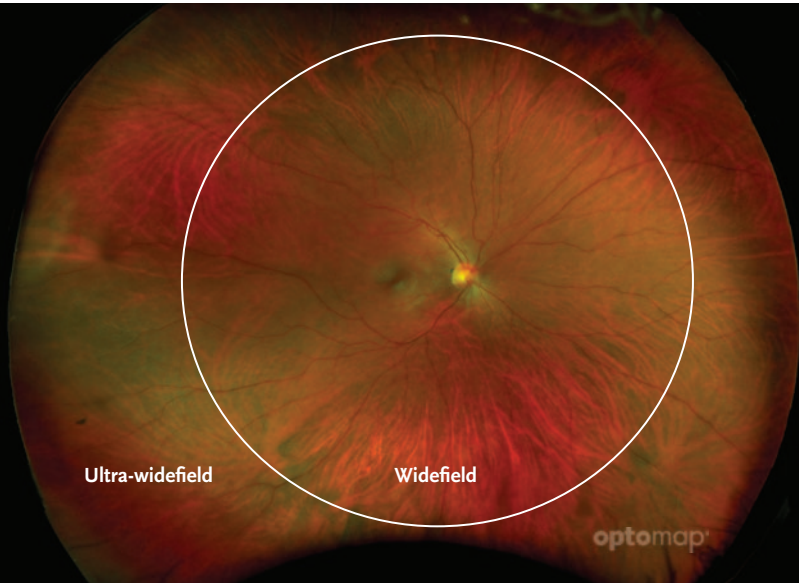

DEFINING ULTRA-WIDEFIELD



Results from a recent publication call for the use of consistent nomenclature when describing the field of view captured by retinal images.

- The International Widefield Imaging Study Group has proposed the need for consistent nomenclature for widefield and ultra-widefield imaging based on normal anatomic landmarks.
- The panel defines ultra-widefield as images showing retinal anatomy anterior to the vortex vein ampullae in all four quadrants. Widefield is defined as an image centered on the fovea and includes the retina in all four quadrants posterior to and including the vortex vein ampullae.¹
- Many large studies have underlined the importance of appropriately imaging the periphery to support the detection and management of disease in a variety of areas including: telemedicine screening^{2,3,4}, diabetic retinopathy^{5,6}, age-related macular degeneration⁷, vascular disease⁸, pediatric retinal disease⁹, inflammatory disease^{10,11,12} and even some systemic diseases.
- Consistently, **optomap** imaging has been demonstrated to capture the widest field of view in a single capture of any imaging technology^{14,15,16,17}.

“A single capture image which provides a view of the vortex veins in all four quadrants and beyond, thus meeting the widefield & ultra-widefield definitions, would offer enhanced efficiency in a real-world clinical setting versus a montage image, whether it be manual or automated.”

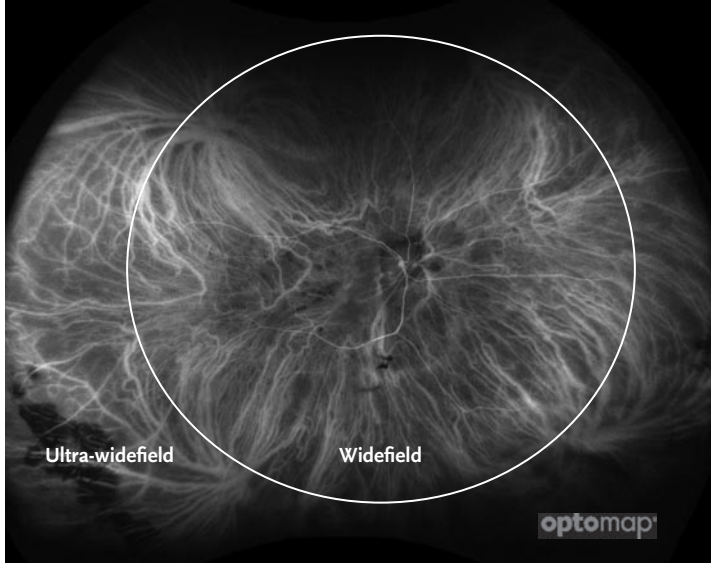
— Netan Choudhry M.D. FRCS(C) DABO

See how **optomap** will help you manage your patients. For more information call **800-854-3039** or email **BDS@optos.com**.



CLINICAL SUMMARY

Defining Ultra-Widefield



optomap *icg* image demonstrating 4 vortex ampullae which define the boundary between widefield and ultra-widefield.

- The International Widefield Imaging Study Group reviewed a set of images from various manufacturers to help support the generation of the following definitions when describing the field of view of retinal images:

Widefield – centered on the fovea and includes the retina in all four quadrants posterior to and including the vortex vein ampullae

Ultra-widefield – images showing retinal anatomy anterior to the vortex vein ampullae in all four quadrants

Pan-retinal – ora to ora image of the retina either in the horizontal or vertical direction

The International Widefield Imaging Study Group, a panel of international retinal imaging experts, has proposed the need for consistent nomenclature for widefield and ultra-widefield imaging based on normal anatomic landmarks. The panel recommends this standardized nomenclature for use in future publications to clarify the capabilities of the technology so they are clear to the reader.

- The new consensus-defined terms help clarify the part of the retina visible in each image and how many images comprise the field of view. This information is important for clinicians assessing which technologies can meet their clinical and research needs. Capturing a larger field of view encompassing more of the retinal periphery is increasingly becoming clinically more important. Given the clinical significance, a clinician must understand the impact on the practice of obtaining those images.
- Following the agreement on retinal imaging terms, the group then reviewed 100 indocyanine green angiograms (ICGs) of both normal and pathological eyes obtained on the Optos California. While the consensus group was device agnostic, it was determined “that images from the Optos California most consistently provide a complete view of the vortex veins and retinal periphery without the need of a montage. Furthermore, the accuracy and precision of quantification of the images has been validated and published.” Optos California is the standard and most widely used ultra-widefield technology, therefore these images were used to calculate the posterior border of the vortex ampullae.¹
- **optomap** imaging has been demonstrated to capture the widest field of view in a single capture of any imaging technology: more than 50% additional retinal area captured versus one single-capture widefield lens based system¹⁴, 110° more than a single capture widefield image and 65° more than the montaged ultra-widefield image from another lens based camera system¹⁶, more vortex veins visualized¹⁵ and statistically significantly more retinal surface area.^{17,18}

References: 1. Classification & Guidelines for Widefield Imaging Recommendations from the International Widefield Imaging Study Group. *Ophthalmology Retina*. 2019. 2. Potential Efficiency Benefits of Nonmydriatic Ultrawide field Retinal Imaging in an Ocular Telehealth diabetic retinopathy program. *Diabetes Care*. 2013. 3. Identification of diabetic retinopathy and Ungradable Image rate with Ultrawide field Imaging in a national Teleophthalmology program. *Ophthalmology*. 2016. 4. A novel hybrid fixed and mobile ultrawide field imaging program for diabetic tele-retinopathy screening. *Ophthalmology Retina*. 2019. 5. Comparison of Early Treatment Diabetic Retinopathy Study Standard-Field Imaging With Ultrawide-Field Imaging for Determining Severity of Diabetic Retinopathy. *JAMA Ophthalmology*. 2018. 6. Peripheral Lesions Identified on Ultrawide Field Imaging Predict Increased Risk of Diabetic Retinopathy Progression over 4 Years. *Ophthalmology* 2015. 7. Peripheral retinal changes associated with age-related Macular degeneration in the age-related eye disease study 2. *Ophthalmology*. 2017. 8. Area of Peripheral Retinal Nonperfusion and Treatment Response in Branch and Central Retinal Vein Occlusion. *Retina*. 2014. 9. Pediatric retinal conditions imaged by ultra wide field fluorescein angiography. *Ophthalmic surgery, Lasers and imaging Retina*. 2013. 10. Wide-field retinal imaging in the management of non-infectious posterior uveitis. *American Journal of Ophthalmology*. 2012. 11. Comparison of Wide-Field Fluorescein Angiography and Nine-Field Montage Angiography in Uveitis. *American Journal of Ophthalmology*. 2014. 12. Peripheral Findings and Retinal Vascular Leakage on Ultra-Widefield Fluorescein Angiography in Patients with Uveitis. *Ophthalmology Retina*. 2017. 13. Peripheral Retinal Imaging Biomarkers for Alzheimer’s Disease: A Pilot Study. *Ophthalmic Research*. 2018. 14. Comparison of ultra-widefield fluorescein angiography with the heidelberg spectralis® noncontact ultra-widefield module versus the optos® optomap®. *clinical ophthalmology*. 2013. 15. Assessment of diabetic retinopathy using two ultra widefield fundus imaging systems the Clarus and Optos systems. *Hirano. BMC Ophthalmology*. 2018. 16. Zeiss 510(k) K181444. 17. Comparison of widefield confocal laser scanning ophthalmoscopy and broad line fundus imaging in retinal ophthalmoscopy and broad line fundus imaging in retinal disease in routine clinical practice. *ARVO* 2019. 18. Quantitative Comparison of Retinal Pixel Area Imaged by UltraQuantitative Comparison of Retinal Pixel Area Imaged by UltraWide Field Fundus Cameras. *ARVO* 2019.



Optos plc
Tel: +44 (0)1383 843350
ics@optos.com

Optos, Inc.
Tel: 800 854 3039
Tel: 508 787 1400
usinfo@optos.com

Optos Australia
Tel: +61 8 8444 6500
auinfo@optos.com

