

**Advancing the Detection  
and Management of  
Diabetic Retinopathy with  
Ultra-widefield Retinal  
Imaging**

David M Brown

**The Impact of Ultra-  
widefield Retinal Imaging  
on Practice Efficiency**

Paul E Tornambe

**The Role of Ultra-widefield  
Retinal Imaging as a  
Standard Assessment Tool  
in the Cataract Practice**

Kerry K Assil and V Nicholas Batra

**US  
Ophthalmic  
Review**

SUPPLEMENT



# Advancing the Detection and Management of Diabetic Retinopathy with Ultra-widefield Retinal Imaging

David M Brown

Retina Consultants of Houston, Houston, Texas, US and The Methodist Hospital–Weill Cornell Medical College, New York, New York, US

The incidence of diabetes in the US population has increased more than fourfold over the last several decades and a high proportion of these patients manifest diabetic eye disease, including diabetic retinopathy (DR) and diabetic macular edema (DME). Ultra-widefield (UWF) retinal imaging has emerged as a valuable tool in the evolving standard of care for DR, providing essential visualization of ischemia and related pathology across the retina, particularly in the periphery, where these signs may appear earliest but may not be detected by conventional fundus photography. Multimodal UWF imaging has helped correlate changes in the periphery with DR progression, providing important guidance for treatment planning and facilitating improved understanding of the underlying mechanisms of disease. Rapid capture, immediate retrieval and efficient sharing of UWF retinal images support a wide spectrum of care settings—including teleophthalmology programs—and facilitate patient education.

## Keywords

Ultra-widefield retinal imaging, diabetic retinopathy, fluorescein angiography, retinal periphery, ischemia, pan-retinal photocoagulation, teleophthalmology

**Disclosure:** David M Brown is a consultant for Heidelberg, Optos, Optovue, and Zeiss.

**Acknowledgements:** Editorial assistance was provided by BioComm Network, Inc.

**Compliance with Ethics:** This study involves a review of the literature and did not involve any studies with human or animal subjects performed by any of the authors.

**Authorship:** The named author meets the International Committee of Medical Journal Editors (ICMJE) criteria for authorship of this manuscript, takes responsibility for the integrity of the work as a whole, and has given final approval to the version to be published.

**Open Access:** This article is published under the Creative Commons Attribution Noncommercial License, which permits any noncommercial use, distribution, adaptation, and reproduction provided the original author(s) and source are given appropriate credit.

**Received:** January 27, 2017

**Accepted:** March 10, 2017

**Citation:** *US Ophthalmic Review*, 2017;10(1):23–6

**Corresponding Author:** David M Brown, Retina Consultants of Houston, 6560 Fannin, Suite 750 Houston, TX 77030, US. E: dmbmd@houstonretina.com

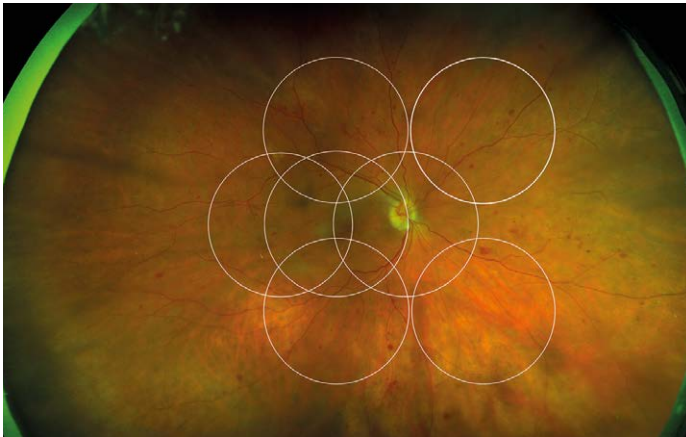
**Support:** The publication of this article was supported by Optos. The views and opinions expressed are those of the author and do not necessarily reflect those of Optos.

Diabetic retinopathy (DR) is one of the leading causes of adult vision loss in the developed world.<sup>1,2</sup> Epidemiological and demographic factors, including the rising rates of diabetes related to obesity and an aging population, are driving the incidence of diabetic eye disease inexorably higher. Over the past 35 years, the number of Americans diagnosed with diabetes increased fourfold, from 5.5 million in 1980 to 22.0 million in 2014.<sup>3</sup> In 2014, approximately 8 million Americans with diabetes were undiagnosed, making the total incidence of the disease in the US more than 29 million, or 9.3% percent of the population.<sup>4</sup> Analyses based on data collected a decade ago in the National Health and Nutrition Examination Survey (NHANES) suggest that nearly a third of all adults with diabetes in the US had signs of DR. This rate was even higher among specific populations of diabetic patients, with more than a third of Mexican Americans and nearly 40% of African Americans having diabetic eye disease. Patients in these groups were also more likely to present with severe disease and vision loss. Overall, an estimated 4.2 million adults had DR at that time and 655,000 had disease severe enough to be vision threatening.<sup>5</sup> Given the data showing that the at-risk population has continued to grow at a similar rate, the clinical community must take aggressive action toward earlier identification and treatment of patients with DR. Meeting this challenge requires improved access to screening and referral as well as enhanced strategies for earlier detection, evaluation, treatment, and assessment of treatment success.

In this setting, digital, multi-modality ultra-widefield (UWF™) retinal imaging (Optos, plc., Dunfermline, Scotland) provides a technological cornerstone for the evolving standard of care. With a single, non-contact capture, UWF retinal imaging allows high-resolution visualization of up to 82%, or 200 degrees, of the retina (producing the digital optomap®), displaying the most retinal surface area of any available imaging system.<sup>6</sup> Optos systems incorporate a proprietary scanning laser ophthalmoscope (SLO) and ellipsoidal mirror, engineered specifically for UWF imaging. The SLO utilizes two low-power lasers that scan the retina simultaneously, with the green ‘red free’ wavelength (532 nm) permitting visualization of the sensory retina to the retinal pigment epithelium (RPE) and the red wavelength (635 nm) reaching deeper structures from the RPE to the choroid. The latest generation Optos UWF platform, California, utilizes enhanced optical hardware and software to improve resolution during scanning, producing clear, high-resolution images of virtually the entire retina. The automatic montage feature increases the field of view in many eyes to greater than 95%.<sup>7</sup> California provides multi-modality imaging options including color, autofluorescence (AF), fluorescein angiography (FA), and indocyanine green angiography (ICG).



Figure 1: optomap of proliferative diabetic retinopathy with ETDRS 7-standard field overlay

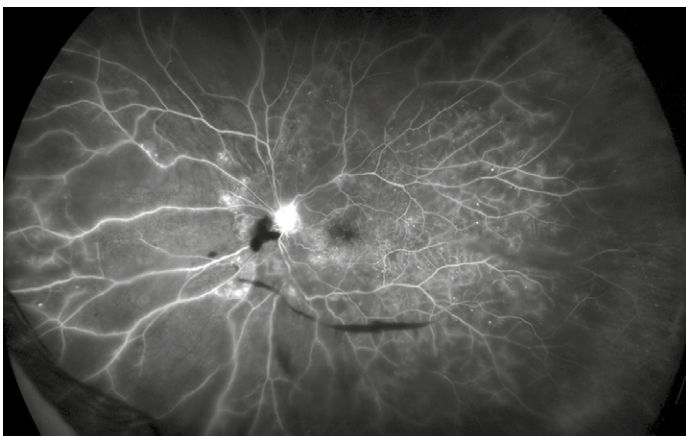


ETDRS = Early Treatment Diabetic Retinopathy Study.

Figure 2: optomap demonstrating proliferative diabetic retinopathy

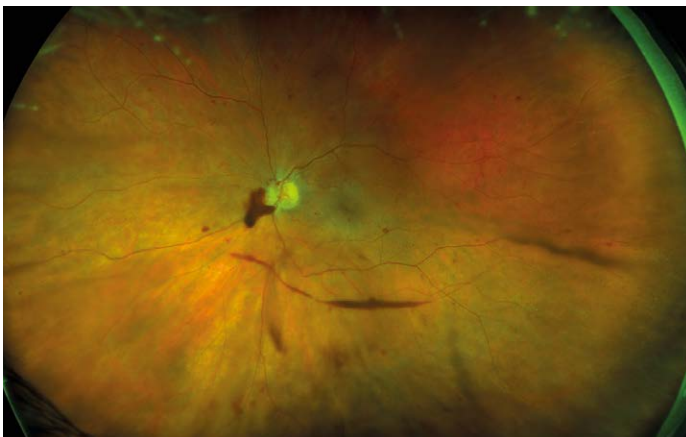

Figure 3: optomap FA demonstrating proliferative diabetic retinopathy with areas of non-perfusion and leakage outside the central pole



FA = fluorescein angiography. Image courtesy of Srinivas Sadda, MD.

## Ultra-widefield imaging in diabetic retinopathy detection and evaluation

The potential role of UWF imaging in the detection of DR has been described for nearly a decade.<sup>8</sup> Early studies established the excellent correspondence between conventional Early Treatment Diabetic Retinopathy Study (ETDRS) 7-fields and optomap in evaluating DR and verified that UWF enabled the visualization of a much larger area of the peripheral retina (see *Figure 1*).<sup>9,10</sup> One comparison in 103 patients with diabetes confirmed the correlation of conventional fundus photography and UWF images in DR assessment, while demonstrating that optomap required less than half the image capture time.<sup>11</sup> Because at least two-thirds of potential retinal pathology lies in the periphery, UWF color and FA images allow the detection of vascular nonperfusion, peripheral microaneurysms, neovascularization, and vascular leakage that are missed by conventional ETDRS 7-fields photography. These peripheral lesions often occur earlier in the disease course; they may also provide evidence of more advanced disease.<sup>12-14</sup> Combining UWF capabilities with ocular coherence tomography (OCT) has also been shown to have clinical utility in the assessment of DR.<sup>15</sup>

The capabilities of UWF retinal imaging are proving particularly useful in efforts to expand screening programs for DR, particularly in teleophthalmology settings for underserved, high-risk populations. Because optomap images can be captured, stored, and shared easily, even between practices that do not have Optos imaging systems, diagnostic efficiency, referral speed, and resource utilization can be improved in an increasingly time- and cost-constrained environment. In one diabetes teleophthalmology program, utilization of nonmydriatic UWF imaging shortened the time required for image evaluation by 28% and reduced the ungradable rate to less than 3%, compared with conventional imaging, while increasing the detection of DR by 17%.<sup>16</sup> The same group studied nonmydriatic UWF imaging in a multi-state DR ocular telehealth program administered for the Indian Health Service. They found that, compared with non-mydriatic fundus photography, UWF imaging in this setting reduced the ungradable image rate by 81%, increased DR detection by nearly twofold, and identified peripheral lesions suggestive of more severe DR in nearly 10% of patients.<sup>17</sup>

## The importance of examining the periphery in diabetic retinopathy

In addition to the fact that a significant amount of pathology associated with DR lies outside the central fields, a growing body of evidence points to the retinal periphery as a locus of early signs of diabetic eye disease and a source of important indications of its progression. Ischemia, a key driver of progression in DR, may appear first in the retinal periphery, well beyond the range of traditional angiography. A close association between predominantly peripheral lesions, the extent of nonperfusion and ischemia, and DR severity has been demonstrated with UWF FA.<sup>18</sup> Analogous to trees shedding peripheral leaves in times of drought, and frostbite affecting distal extremities as the body works to preserve critical central organs, the human retina can experience marked peripheral capillary loss well before evidence of central pathology. Identifying the presence and extent of ischemia across the entire retina may permit more accurate assessment and effective management, particularly in staging anti-vascular endothelial growth factor (VEGF) treatments with photocoagulation (see *Figures 2 and 3*).<sup>19</sup> Indeed, the value of UWF imaging in linking the extent of peripheral ischemia to the presence or potential development of diabetic macular edema (DME) and worsening disease, has been evaluated in several studies. Peripheral

ischemia, detected on UWF FA, has been strongly correlated with DME in treatment-naïve patients.<sup>20</sup> Other investigators have proposed a new ischemic index based on UWF findings. This work established the relationship between peripheral nonperfusion, severity of DR, and recalcitrant macular edema, while suggesting that areas of untreated peripheral nonperfusion may be the source of mediators of ischemia and disease progression.<sup>21</sup> The potential prognostic value of peripheral lesions identified with UWF was confirmed in a study that demonstrated the association of these findings with a significantly increased risk of disease progression over a four-year period, independent of baseline severity of DR or diabetic control.<sup>22</sup> These observations suggest that the established '4-2-1' rule for identifying severe non-proliferative DR and a high risk for disease progression, based on the evaluation of signs identified through conventional imaging of the central fields (diffuse intraretinal hemorrhages and microaneurysms in four quadrants, venous beading in two or more quadrants, or intraretinal microvascular abnormalities in one or more quadrants), may underestimate DR severity compared with findings in the periphery from UWF imaging. A multi-year study that will enroll at least 350 participants is being conducted by the Diabetic Retinopathy Clinical Research Network (DRCRnet) to further establish the impact of UWF evaluation of the retina on the assessment of DR and in predicting rates of DR progression over time, compared with conventional ETDRS 7-fields.<sup>23</sup>

### The use of ultra-widefield retinal imaging in treatment planning

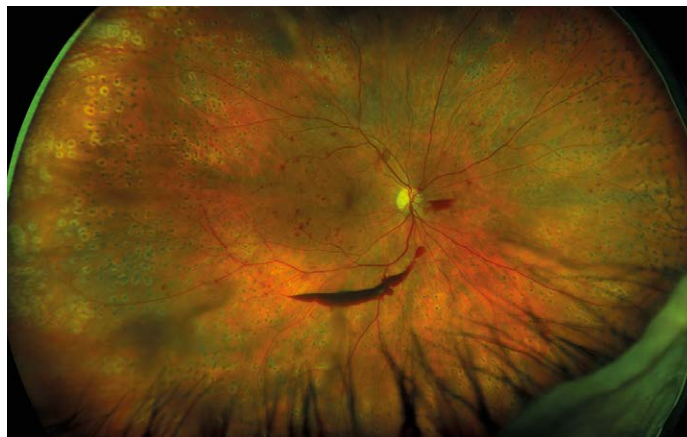Visualization of the entire retina may provide a rationale to initiate treatment earlier and arrest progression sooner. This hypothesis is supported by the results of the Ranibizumab Injection in Subjects With Clinically Significant Macular Edema With Center Involvement Secondary to Diabetes Mellitus (RIDE and RISE) studies, which demonstrated that greater improvements in vision were achieved in eyes treated within the first two years, compared to eyes with chronic DME associated with irreversible damage to the retina.<sup>24</sup> Findings from peripheral examination have allowed us to intervene in cases of proliferative retinal vein occlusion before a hemorrhage occurs, reduce the number of vitrectomies we perform for floaters, and identify neovascularization earlier. The value of acting earlier is supported by data confirming that patients with post vitrectomy diabetic vitreous hemorrhage display higher rates of neovascularization, nonperfusion, and late vascular leakage in the periphery.<sup>25</sup>

Peripheral findings also provide important information about which areas of the retina should be treated. Our experience suggests that identifying areas of ischemia with UWF allows more precise targeting of pan-retinal photocoagulation (PRP) to retinal pathology while sparing areas that remain adequately perfused. Sparing of useful visual field (especially nasal and superior retina) can help preserve inferior and temporal depth perception important for walking down stairs or curbs and making driving safer. Finally, UWF retinal imaging can be employed to evaluate treatment success (see *Figures 4, 5, and 6*). For example, documentation with UWF FA of reperfusion in areas of nonperfusion following anti-VEGF treatment was recently described.<sup>26</sup>

### Improving clinical and patient communication

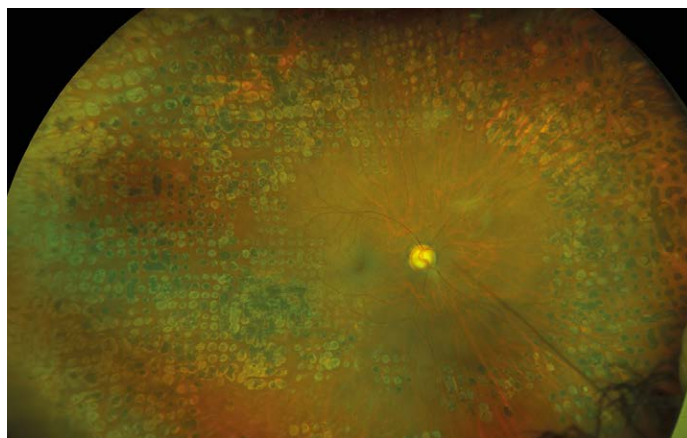
The immediate availability of multimodal optomap images following single-shot, nonmydriatic capture permits more efficient evaluation at the point of care. Remote review at a reading center or in other practices is facilitated by browser-based, platform-independent (DICOM compatible), Health

**Figure 4: optomap demonstrating diabetic retinopathy with panretinal photocoagulation and pre-retinal and retinal hemorrhages in the periphery**




*Image courtesy of Paul Stanga, MD.*

**Figure 5: optomap of diabetic retinopathy with panretinal photocoagulation in the periphery**



*Image courtesy of Srinivas Sadda, MD.*

**Figure 6: optomap FA of diabetic retinopathy with panretinal photocoagulation in the periphery with a quiet central pole**



*FA = fluorescein angiography. Image courtesy of Srinivas Sadda, MD.*



Insurance Portability and Accountability Act (HIPAA)-compliant image sharing and cloud storage. This ease of image sharing is particularly useful in referral situations or teleophthalmology settings.

In addition to efficient evaluation and annotation by the clinical team, a single optomap or historical comparisons can be reviewed with the patient without delay during the office visit on a computer screen or tablet. While diabetes affects small blood vessels all over the body, DR is often the first manifestation of end-organ disease that can be detected. Many patients with diabetes are non-compliant with blood sugar control and are in denial that this is detrimental to their physical health and end organs. We have found that counseling a patient on improving blood sugar control while demonstrating with UWF imaging that damage is already occurring in their peripheral retina is often a very effective and convincing approach to education and behavior modification. We review the optomap with the patient and their care partners, pointing out microaneurysms and capillary non-perfusion. We advise them that if damage is occurring in

the retina, then it is also happening in the heart, the kidneys, the brain, and throughout their body. In our experience, the immediacy of this vivid demonstration of the impact of their lack of adherence on the blood vessels in their body, particularly if historical comparison has indicated progression, helps patients and their loved ones realize that they need to become more serious about glycemic control and other aspects of their treatment plan.

## Conclusion

The dramatic increase in the incidence of diabetes and associated eye disease will continue to pose a challenge for the clinical community. In this environment, UWF retinal imaging is valuable for effective screening, refinement of treatment decision-making, and advancement of our understanding of the disease process itself. By facilitating earlier diagnosis, earlier treatment, and more effective patient education, UWF retinal imaging is helping to shape the new standard of care for DR that will preserve vision for more of our patients with diabetes. □

- Bourne RRA, Stevens GA, White RA, et al., Causes of vision loss worldwide, 1990-2010: a systematic analysis, *Lancet*, 2013;1:e339–e349.
- Lee R, Wong TY, Sabanayagam C, Epidemiology of diabetic retinopathy, diabetic macular edema and related vision loss, *Eye Vis*, 2015;2:17.
- Centers for Disease Control and Prevention, National Center for Health Statistics, Division of Health Interview Statistics, data from the National Health Interview Survey. Available at: [www.cdc.gov/diabetes/statistics/prev/national/figpersons.htm](http://www.cdc.gov/diabetes/statistics/prev/national/figpersons.htm) (accessed March 13, 2017).
- Centers for Disease Control and Prevention, National Diabetes Statistics Report: Estimates of Diabetes and Its Burden in the United States, 2014, Atlanta, GA: US, Department of Health and Human Services, 2014.
- Zhang X, Saaddine JB, Chou C, et al., Prevalence of diabetic retinopathy in the United States, 2005-2008, *JAMA*, 2010;304:649–56.
- Witmer MT, Parlitsis G, Patel S, et al., Comparison of ultra-widefield fluorescein angiography with the Heidelberg Spectralis® noncontact ultra-widefield module versus the Optos® Optomap®, *Clin Ophthalmol*, 2013;7:389–94.
- Optos. Data on file. 2017.
- Kaines A, Oliver S, Reddy S, Schwartz SD, Ultrawide angle angiography for the detection and management of diabetic retinopathy, *Int Ophthalmol Clin*, 2009;49:53–9.
- Kerrt M, Hadi I, Pinter F, et al., Assessment of diabetic retinopathy using nonmydriatic ultra-widefield scanning laser ophthalmoscopy (optomap) compared with ETDRS 7-field stereo photography, *Diabetes Care*, 2012;35:2459–63.
- Kerrt M, Pinter F, Hadi I, et al., Diabetic retinopathy: comparison of the diagnostic features of ultra-widefield scanning laser ophthalmoscopy Optomap with ETDRS 7-field fundus photography [article in German], *Ophthalmologe*, 2011;108:117–23.
- Silva PS, Cavallerano JD, Sun JK, et al., Nonmydriatic ultrawide field retinal imaging compared with dilated standard 7-field 35-mm photography and retinal specialist examination for evaluation of diabetic retinopathy, *Am J Ophthalmol*, 2012;154:549–59.
- Wessel MM, Aaker GD, Parlitsis G et al., Ultra-wide-field angiography improves the detection and classification of diabetic retinopathy, *Retina*, 2012;32:785–91.
- Kong M, Lee MY, Ham DI, Ultrawide-field fluorescein angiography for evaluation of diabetic retinopathy, *Korean J Ophthalmol*, 2012;26:428–31.
- Silva PS, Cavallerano JD, Sun JK, et al., Peripheral lesions identified by mydriatic ultrawide field imaging: distribution and potential impact on diabetic retinopathy severity, *Ophthalmology*, 2013;120:2587–95.
- Manjunath V, Papastavrou V, Steel DHW, et al., Wide-field imaging and OCT vs clinical evaluation of patients referred from diabetic retinopathy screening, *Eye*, 2015;29:416–23.
- Silva PS, Cavallerano JD, Tolls D, et al., Potential efficiency benefits of nonmydriatic ultrawide field retinal imaging in an ocular telehealth diabetic retinopathy program, *Diabetes Care*, 2014;37:50–5.
- Silva PS, Horton MB, Clary D, et al., Identification of diabetic retinopathy and ungradable image rate with ultrawide field imaging in a national teleophthalmology program, *Ophthalmology*, 2016;123:1360–7.
- Silva PS, Dela Cruz AJ, Ledesma MG, et al., Diabetic retinopathy severity and peripheral lesions are associated with nonperfusion on ultrawide field angiography, *Ophthalmology*, 2015;122:2465–72.
- Takamura Y, Tomomatsu T, Matsumura T, et al., The effect of photocoagulation in ischemic areas to prevent recurrence of diabetic macular edema after intravitreal bevacizumab injection, *Invest Ophthalmol Vis Sci*, 2014; 55:4741–6.
- Wessel MM, Nair N, Aaker GD, et al., Peripheral retinal ischaemia, as evaluated by ultra-widefield fluorescein angiography, is associated with diabetic macular oedema, *Br J Ophthalmol*, 2012;96:694–8.
- Patel RD, Messner LV, Teitelbaum B, et al., Characterization of ischemic index using ultra-widefield fluorescein angiography in patients with focal and diffuse recalcitrant diabetic macular edema, *Am J Ophthalmol*, 2013;155:1038–44.
- Silva PS, Cavallerano JD, Haddad NMN, et al., Peripheral lesions identified on ultrawide field imaging predict increased risk of diabetic retinopathy progression over 4 years, *Ophthalmology*, 2015;122:949–56.
- DRCR.net Protocol. Available at: <http://drcrnet.jaeb.org/Studies.aspx?ReclID=239> (accessed March 31, 2017).
- Brown DM, Nguyen QD, Marcus DM, et al., Long-term outcomes of ranibizumab therapy for diabetic macular edema: The 36-month results from two phase III trials (RISE and RIDE), *Ophthalmology*, 2013;120:2013–22.
- Kim DY, Kim J-G, Kim JY, et al., Ultra-widefield fluorescein angiographic findings in patients with recurrent vitreous hemorrhage after diabetic vitrectomy, *Invest Ophthalmol Vis Sci*, 2014;55:7040–6.
- Levin AM, Rusu I, Orlin A, et al., Retinal reperfusion in diabetic retinopathy following treatment with anti-VEGF intravitreal injections, *Clinical Ophthalmology*, 2017;11:193–200.

# The Impact of Ultra-widefield Retinal Imaging on Practice Efficiency

Paul E Tornambe

Retina Consultants, San Diego, California, US, and San Diego Retina Research Foundation, San Diego, California, US

In the current cost- and resource-constrained healthcare environment in the United States, characterized by declining government reimbursement and increased utilization scrutiny by managed care plans, providers are challenged to continue delivering quality care to more patients while also more effectively managing practice economics. Employing technology to improve practice efficiency is one of the most promising solutions to this dilemma. We have demonstrated that the integration of ultra-widefield (UWF) retinal imaging in our practice is cost-effective. It has allowed us to increase the number of patient encounters while simultaneously raising the quality of care, and increasing patient satisfaction.

## Keywords

Ultra-widefield retinal imaging, UWF, practice efficiency, patient volume, cost-effectiveness, quality care, retinal periphery, patient satisfaction

**Disclosure:** Paul E Tornambe is a consultant to Optos.

**Acknowledgements:** Editorial assistance was provided by BioComm Network, Inc.

**Compliance with Ethics:** This study is based on data collected within the practice over a three year period as well as a review of the literature and did not involve any studies with human or animal subjects performed by the author.

**Authorship:** The named author meets the International Committee of Medical Journal Editors (ICMJE) criteria for authorship of this manuscript, takes responsibility for the integrity of the work as a whole, and has given final approval to the version to be published.

**Open Access:** This article is published under the Creative Commons Attribution Noncommercial License, which permits any noncommercial use, distribution, adaptation, and reproduction provided the original author(s) and source are given appropriate credit.

**Received:** February 6, 2017

**Accepted:** March 10, 2017

**Citation:** *US Ophthalmic Review*, 2017;10(1):27–30

**Corresponding Author:** Paul E Tornambe, 12630 Monte Vista Rd, Poway, CA 92064, US. E:tornambe@aol.com

**Support:** The publication of this article was supported by Optos. The views and opinions expressed are those of the author and do not necessarily reflect those of Optos.

Ophthalmic medical practices in the United States are under unprecedented pressure to care for a rapidly growing population of patients, even as Medicare reimbursement levels continue to decline and payers are implementing payment programs based on cost and quality metrics. The Centers for Medicare and Medicaid Services (CMS) has continued to enact significant cuts to payment rates for a range of ophthalmic procedures, from glaucoma surgery to retinal detachment repair and various diagnostic imaging procedures. These are only the latest changes to the economics of care delivery to which ophthalmologists must rapidly adjust. More than ever, the financial viability of the ophthalmology practice depends on its ability to deliver efficient care – integrating cost, quality, outcomes, and patient satisfaction – within an ever-changing landscape of medical innovation, government regulation, payer intervention, and patient expectation.

Several years ago, we formally evaluated the relative efficiency of academic hospital center and small group practices by applying activity-based cost analysis to both settings.<sup>1</sup> We found that the small group practice outperformed the academic medical center on nearly all markers of efficiency. In the latter setting, only four service lines – non-laser surgery (e.g., pneumatic retinopexy, pars plana vitrectomy, scleral buckling surgery), laser surgery (e.g., pan-retinal photocoagulation, retinal tear repair), diagnostic imaging other than optical coherence tomography (OCT) (e.g., fundus imaging and ultrasound), and injections – were profitable, with profit margins ranging from 62% for non-laser surgery to 1% for intravitreal injections. The largest negative profit contributions were generated by office visits and OCT imaging. The continued reduction of reimbursement rates for both diagnostic services and therapeutic injections in the intervening years has made conditions even more challenging for both types of practice and has increased the critical importance of evaluating and improving efficiency. Various models for measuring and comparing practicing efficiency are in development. For example, an efficiency index, calculated as a function of cost, number of patients receiving care, and the quality of care, has been proposed to measure the care delivery process for a given intervention within the ophthalmic practice.<sup>2</sup> As such models are expanded to include outcome measures and are validated in larger inter-practice comparisons they may be useful in efforts to improve both the quality and efficiency of care.

Regardless of how efficiency is measured, it is increasingly clear that one key to the challenge of simultaneously improving practice efficiency and quality of care amid relentless financial pressure is the use of advanced technology – diagnostic and treatment systems that provide more useful clinical information, more rapidly, and with greater comfort or convenience for patients. An example along these lines is the positive impact on efficiency and quality of care in cataract and refractive practices produced by the integration of wavefront technology. The impact of this technology for digital refraction and optical path diagnostics was recently described, with the authors noting that the speed and comprehensiveness of total visual system assessment improved outcomes, patient

Figure 1: optomap of a retinal hole and horseshoe tear with a cuff of subretinal fluid found in the inferior temporal periphery

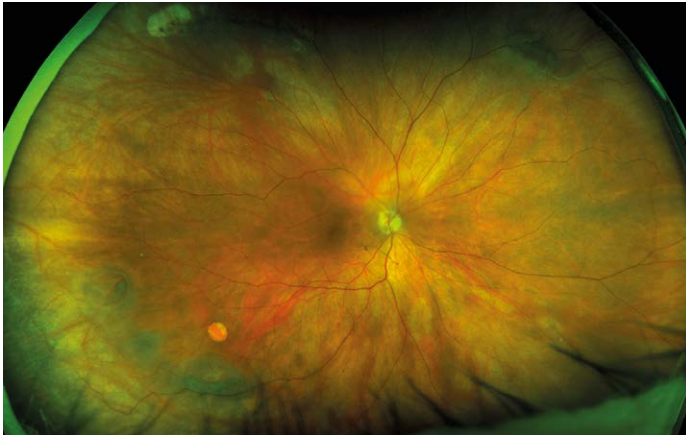

Image courtesy of William Keeling, MD.

Figure 2: optomap showing a temporal retinal detachment with a horseshoe tear in the far superior periphery

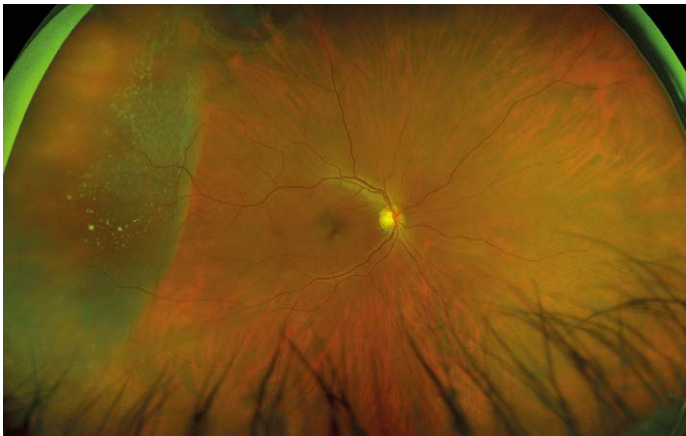


Figure 3: optomap demonstrating a choroidal melanoma nasal to the disc with peripapillary lipid exudation

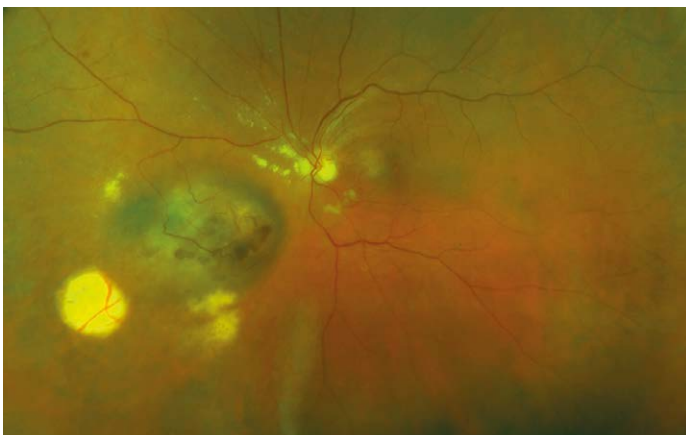

Image courtesy of Duke Eye Center.

satisfaction and cost-effectiveness.<sup>3</sup> We have seen analogous benefits in our practice from the routine use of ultra-widefield (UWF™) retinal imaging using the Optos system. This paper will describe how the integration of UWF retinal imaging improved efficiency and quality of care, enhanced patient satisfaction, and allowed more patients to be examined during a fixed time interval in our practice. We show that the resulting increase in patient volume can improve cash flow irrespective of reimbursement rates or how payments for testing are bundled.

### Elements of efficiency for diagnostic imaging

The unparalleled field of view (sometimes called “pan-retinal” imaging), rapid, patient-friendly image capture, high-resolution, and easy transmission of UWF optomap® (Optos, plc. Dunfermline, Scotland) imaging make it well suited to enhancing the efficiency and quality of ophthalmic care. The Optos system provides the widest field of view of any retinal imaging platform.<sup>4</sup> The high-resolution digital image it produces is obtained in a single, non-contact, often non-mydratic capture lasting about a second; the image is immediately available for evaluation by the clinician and review with the patient on a computer screen or tablet. Cross-registration of different imaging modalities or prior images is instantaneous, supporting comprehensive evaluation of retinal pathology or disease progression. The systems are DICOM compatible and utilize cloud-based transmission and storage to facilitate image sharing with other offices and practices, as well as archiving as part of the medical record.

A growing body of research has demonstrated the potential of UWF imaging to improve detection, documentation, and management of retinal pathology, particularly in zones of the periphery outside the field of view of conventional imaging. The potential of UWF imaging to improve the diagnosis and management of diabetic retinopathy (DR), one of our principle areas of clinical interest, is well documented.<sup>5</sup> Multiple investigators have favorably compared UWF to conventional Early Treatment Diabetic Retinopathy Study (ETDRS) 7-fields, the standard DR assessment tool, observing that optomap images cover a much larger area of the retina, despite being acquired much more quickly and often without dilation.<sup>6-8</sup> Our own experience supports the conclusions of these and other studies which confirm that the use of UWF color imaging and UWF FA result in the detection of more pathology, including early signs of DR progression such as peripheral microaneurysms, neovascularization, vascular nonperfusion, and vascular leakage. These key indicators of disease severity might be missed or minimized by exams depending on standard field imaging.<sup>9-11</sup> The greater accuracy and efficiency of UWF imaging has proven particularly useful in teleophthalmology. In one national ocular telehealth program focused on DR, nonmydratic UWF imaging reduced the ungradable image rate by 81%, nearly doubled the identification of DR, and identified peripheral lesions suggestive of more severe disease in nearly 10% of patients, compared to nonmydratic multi-field fundus photography.<sup>12</sup>

We have consistently seen similar benefits in our practice and have carefully evaluated the impact of UWF retinal imaging on the quality, cost-effectiveness and revenue potential of the care we deliver, as well as its contribution to patient satisfaction.

### UWF improves the quality of care

Fundamentally, quality in the context of the medical practice is doing the right thing, correctly, the first time. By this definition, each diagnostic procedure performed should provide the necessary support for the



subsequent interventions. In examining the impact of UWF on quality, we should recognize that the optomap does not replace the retinal examination, particularly of the periphery, or scleral depression but it facilitates this examination by providing a pan-retinal overview allowing the clinician to focus attention on pathological findings of interest. Since the upper eye lid may limit visualization of the inferior retina, examination of the peripheral retina is still necessary. The use of UWF also improves workflow efficiency by decreasing the technician time required for image acquisition and decreasing the time the patient must spend in the waiting room. Furthermore, as the extensive literature suggests, employing UWF first, on every patient, ensures that our team does not miss pathology, such as melanomas, retinal detachments, or DR, even on the busiest clinic day (see *Figures 1–3*). UWF imaging often reveals pathology that might be overlooked during the clinical exam, including signs of systemic disease, such as subtle vascular sheathing or rare microaneurysms, suggestive of diabetes, hypertension or carotid disease, in patients with no such diagnosis or symptoms. In fact, our experience reflects published studies that suggest UWF retinal imaging can be an outstanding screening tool – rapid and easy to perform, convenient for the patient, clinically useful, and readily shared. Finally, in situations with media changes, such as gas bubbles following retinal surgery, or in patients with small pupils or those who cannot tolerate a full exam, UWF provides the most effective way to examine the retina.

### UWF improves the cost-effectiveness of care

When considering cost-effectiveness, clinicians must assess whether the revenue produced by a new technology is sufficient to cover the cost of its acquisition and whether a particular unit of care can be delivered in a profitable way for the practice. This means it must be acceptable to the payer and reimbursed at a revenue positive level. We have examined several potential impacts of UWF retinal imaging on revenue drivers in our practice, including its potential to increase the number of billable photographs and angiograms we take and the number of laser treatments we perform. We reviewed yearly patient encounters prior to and one and two years following the installation of our UWF retinal imaging system. With the use of UWF, the absolute number of photographs taken has increased; however, since not every image is considered medically-necessary by payer rules, the revenue contribution of this increase was relatively minor (for our analysis, we've assumed only a 50% reimbursement rate). We also documented an increase in FA's and a small number of additional laser treatments, specifically in patients with non-proliferative DR in whom UWF had documented severe peripheral nonperfusion prior to the development of frank neovascularization. The volume change and revenue contributions of these three lines of service after the first year are summarized in *Table 1*.

By far, the most significant financial impact UWF has made in our practice is the increase in the number of patients we are able to see. This is largely the result of the reduction in the 'busy work' component of the office examination, such as noting cup-to-disc ratios, the presence of drusen, or retinal pigment epithelium and vascular changes. The use of UWF also facilitates more rapid determination of changes in peripheral lesions, including tumor growth, sheathing, or intraretinal microvascular abnormalities (IrMA). In the first year after we integrated UWF retinal imaging, we saw 220 more patients, an increase of 4.4% over the pre-UWF period, which was an average of 1.5 additional patient encounters per day. This translated over \$40,000 in incremental revenue. In the second year of

**Table 1: Change in procedure volume and revenue contribution in the first year following the adoption of UWF retinal imaging (comparing the period 9/2009 through 2/2010 to 9/2010 through 8/2011)**

Procedure	Fundus photography	FA	Diabetic laser Tx
Numerical change	+631	+79	+2
Percent change	+70%	+2.2%	(NS)
Revenue contribution*	\$24,552**	\$18,500	(NS)

\*Reimbursement rates at the time of analysis were \$77.82 for fundus photography and \$233.93 for FA. \*\*Assumes 50% were allowed by third-party payer. FA = fluorescein angiography; NS = not significant; Tx = treatment.

UWF use, patient volume increased by 7%. The total incremental revenue generated by the integration of UWF was approximately \$76,000 per year or \$6,333 per month. As a result, the Optos UWF retinal imaging system we purchased paid for itself in just over a year. After 4 years of routine UWF retinal imaging, we have an average exam time of 11 minutes and are able to see 45 patients on a clinic day, with high patient satisfaction. We are now incorporating two 'followers,' one to a Scribe position, the other to care for the immediate needs of post-injection patients, which should further decrease physician 'busy work' time by several minutes per patient, increasing patient capacity to 55 to 60 patients per day. Obviously, the type of visit encounter will affect the number of patient daily encounters. We give all injections at the time of the exam visit, and frequently give bilateral injections for patient convenience. Given that reimbursement rates have continued to decline (in our area, fundus photography is now reimbursed at \$71 and FA at \$92), the contribution of patient volume to the economic equation is even more significant. Of course, the financial benefit of integrating UWF will vary by practice but our experience is generally consistent with anecdotal reports we have heard from other retina offices.

It is worth noting that the combination of declining reimbursement levels and managed care plan payment adjustments based on utilization make the traditional practice of performing multiple diagnostic tests counterproductive from a revenue standpoint. By providing more information from a single test, data which has a direct impact on the quality of care, and by allowing more patients to be examined, UWF retinal imaging represents a new economic model for the ophthalmic practice, based on seeing more patients, not ordering more tests. Discovery and documentation of retinal pathology with an initial optomap also supports reimbursement of subsequent confirmatory tests like a UWF-guided peripheral exam with an indirect ophthalmoscope or OCT. The irrefutable documentation of the status of the retina at the time of the visit may also have beneficial medicolegal implications.

### UWF increases patient satisfaction

Particularly when compared to conventional dilated fundus photography, UWF retinal imaging positively impacts the patient experience. The scanning laser ophthalmoscope (SLO) light is much more comfortable than the bright flash of traditional photography and the speed of image capture significantly reduces the amount of time patients spend in the office not actually receiving care. The reduction of physical exam time and related 'busy work' through the use of UWF retinal imaging also increases the proportion of the visit available for establishing a positive patient/doctor

relationship, as well as patient counseling and education. Furthermore, the value of showing a patient what their actual retina looks like, rather than trying to explain using drawings or models, cannot be overstated. For example, patients who present with a retinal tear can be educated about flashes and floaters with a short video and then see the pathology on their own optomap. This increases their sense of urgency and their willingness to follow the treatment plan. Reviewing their UWF image helps them appreciate the benefits of early detection and understand why prompt treatment is critical to protect their vision.

We have also seen firsthand that improved patient satisfaction provides additional support for the flow of new patients, as happy patients tell their families and friends about their experience. The overall impact of the full

integration of UWF retinal imaging in our practice is an increase of 12% in patient volume.

### Conclusion

In order to thrive in the current healthcare environment, ophthalmic practices must attract and manage larger numbers of patients while simultaneously delivering high-quality, cost-effective care. To balance this equation – to maintain healthy revenue streams while providing quality care – ophthalmologists must utilize technology that will improve practice efficiency. The integration of UWF retinal imaging to produce more clinically-relevant information, more rapidly and in a more patient-friendly manner, can make important contributions to multiple aspects of the efficiency challenge. □

1. Murray TG, Tornambe P, Dugel P, Tong KB, Evaluation of economic efficiencies in clinical retina practice: activity-based cost analysis and modeling to determine impacts of changes in patient management, *Clin Ophthalmol*, 2011;5:913–25.
2. Chen A, Kim EA, Aigner DJ, et al., Index to estimate the efficiency of an ophthalmic practice, *JAMA Ophthalmol*, 2015;133:924–9.
3. Matossian C, Noreika JC, Total visual system assessment – integrating wavefront technology in refractive examinations, *US Ophthalmic Review*, 2016;9:41–5.
4. Witmer MT, Parlitsis G, Patel S, Kiss S, Comparison of ultra-widefield fluorescein angiography with the Heidelberg Spectralis® noncontact ultra-widefield module versus the Optos® Optomap®, *Clin Ophthalmol*, 2013;7:389–94.
5. Kaines A, Oliver S, Reddy S, Schwartz SD, Ultrawide angle angiography for the detection and management of diabetic retinopathy, *Int Ophthalmol Clin*, 2009;49:53–9.
6. Kernt M, Hadi I, Pinter F, et al., Assessment of diabetic retinopathy using nonmydriatic ultra-widefield scanning laser ophthalmoscopy (optomap) compared with ETDRS 7-field stereo photography, *Diabetes Care*, 2012;35:2459–63.
7. Kernt M, Pinter F, Hadi I, et al., Diabetic retinopathy: comparison of the diagnostic features of ultra-widefield scanning laser ophthalmoscopy Optomap with ETDRS 7-field fundus photography [article in German], *Ophthalmologe*, 2011;108:117–23.
8. Silva PS, Cavallerano JD, Sun JK, et al., Nonmydriatic ultrawide field retinal imaging compared with dilated standard 7-field 35-mm photography and retinal specialist examination for evaluation of diabetic retinopathy, *Am J Ophthalmol*, 2012;154:549–59.
9. Wessel MM, Aaker GD, Parlitsis G, et al., Ultra-wide-field angiography improves the detection and classification of diabetic retinopathy, *Retina*, 2012;32:785–91.
10. Kong M, Lee MY, Ham DI, Ultrawide-field fluorescein angiography for evaluation of diabetic retinopathy, *Korean J Ophthalmol*, 2012;26:428–31.
11. Silva PS, Cavallerano JD, Sun JK, et al., Peripheral lesions identified by mydriatic ultrawide field imaging: distribution and potential impact on diabetic retinopathy severity, *Ophthalmology*, 2013;120:2587–95.
12. Silva PS, Horton MB, Clary D, et al., Identification of diabetic retinopathy and ungradable image rate with ultrawide field imaging in a national teleophthalmology program, *Ophthalmology*, 2016;123:1–8.

# The Role of Ultra-widefield Retinal Imaging as a Standard Assessment Tool in the Cataract Practice

Kerry K Assil<sup>1</sup> and V Nicholas Batra<sup>2</sup>

1. Assil Eye Institute, Beverly Hills, California, US; 2. Batra Vision, San Leandro, California, US

**C**omprehensive evaluation of retinal health prior to and following cataract surgery is critical to supporting optimal outcomes. In addition to the importance of identifying retinal pathology that may prevent or delay cataract surgery, continuous advances in refractive intraocular lens technology and cataract surgical technique, coupled with increasingly high expectations regarding visual outcomes among younger patients, make the consideration of long-term quality of vision paramount in the cataract assessment. Optos<sup>®</sup> ultra-widefield retinal imaging supports this clinical objective by providing imaging standardization in a streamlined, patient-friendly exam process, supporting robust documentation that facilitates mapping of disease progression, and offering potential economic advantages in a resource-constrained environment.

## Keywords

Ultra-widefield retinal imaging, UWF, cataract surgery, multifocal IOL, retinal periphery

**Disclosure:** Kerry K Assil has nothing to disclose in relation to this article. V Nicholas Batra participated in a panel case presentation sponsored by Optos

**Acknowledgments:** Editorial assistance was provided by BioComm Network, Inc.

**Compliance with Ethics:** This study a review of the literature and did not involve any studies with human or animal subjects performed by any of the authors.

**Authorship:** All named authors meet the International Committee of Medical Journal Editors (ICMJE) criteria for authorship of this manuscript, take responsibility for the integrity of the work as a whole, and have given final approval to the version to be published.

**Open Access:** This article is published under the Creative Commons Attribution Noncommercial License, which permits any noncommercial use, distribution, adaptation, and reproduction provided the original author(s) and source are given appropriate credit.

**Received:** February 6, 2017

**Accepted:** March 22, 2017

**Citation:** *US Ophthalmic Review*, 2017;10(1):31-4

**Corresponding Author:** Kerry K Assil, 450 N. Roxbury Dr., 3rd Floor, Beverly Hills, CA 90210, US. E: kerry@assileye.com

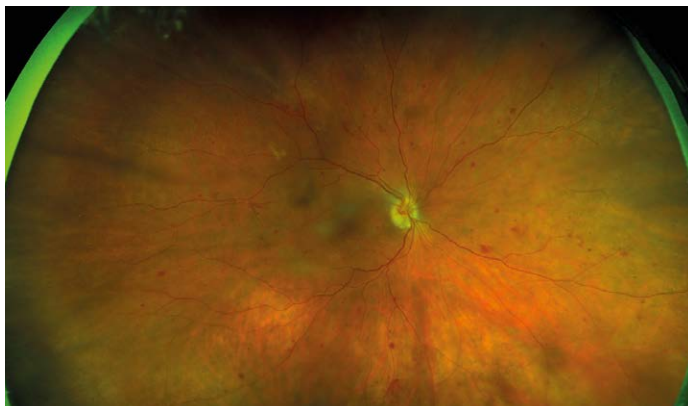
**Support:** The publication of this article was supported by Optos. The views and opinions expressed are those of the authors and do not necessarily reflect those of Optos.

Due in part to continuous improvement in the safety, speed, and refractive outcomes of cataract surgery, the number of cataract procedures has increased steadily over the past 30 years, and the percentage of patients undergoing the procedure at a younger age is also increasing. These trends were documented in a frequently cited population-based study of Omsted County, Minnesota, that compared rates of cataract surgery between 2005 and 2011 to those in the prior 25 years. Data on more than 8,000 cataract procedures in the most recent period revealed that the incidence of cataract surgery had increased significantly, the interval between first and second eye surgery narrowed significantly, and 19% of patients elected cataract surgery before age 65.<sup>1</sup> This rise in cataract surgery rates will continue to accelerate as the US population ages; the number of Americans over age 65 is expected to nearly double by 2050, to 83.7 million.<sup>2</sup>

Along with the increasing volume driven by this large demographic wave, there are a number of important implications of the shift to earlier cataract surgery and the increasing use of sophisticated premium intraocular lens (IOL) technologies. Perhaps the most significant of these is that many patients will live for decades after the procedure. These patients have high expectations of their immediate postoperative visual outcomes and also expect to continue to see well as they age. With sustained quality of vision the main therapeutic objective, it has become paramount to perform thorough retinal exams pre-surgically and postoperatively to identify pre-existing retinal disease that might prevent, delay, or alter surgery, to anticipate future retinal problems—particularly to the degree that this prospect may affect lens choice—and to provide an initial, post-cataract baseline for monitoring future pathological changes. In this review, we will describe the integration into our pre- and post-cataract surgery assessments of a specific imaging technology that has shown utility in retinal disease detection and management for both the general ophthalmologist and the retinal specialist. In our experience, ultra-widefield (UWF<sup>™</sup>) retinal imaging (Optos plc., Dunfermline, Scotland) and the clinical and practical value of the high-resolution, digital optomap<sup>®</sup> images they produce, have complemented the information available to us from standard approaches, including conventional fundus examination and optical coherence tomography (OCT), thereby improving our ability to rapidly and accurately identify retinal pathology, facilitating consultation with retina colleagues, and resulting in enhanced patient care, increased patient satisfaction, and greater efficiency within our practices. As a result, Optos<sup>®</sup> UWF retinal imaging has become a routine component of perioperative evaluation in our cataract cases, based on the unique advantages of the technology, and we believe that other cataract practices may benefit from considering this approach.



Figure 1: optomap of proliferative diabetic retinopathy visible through a cataract

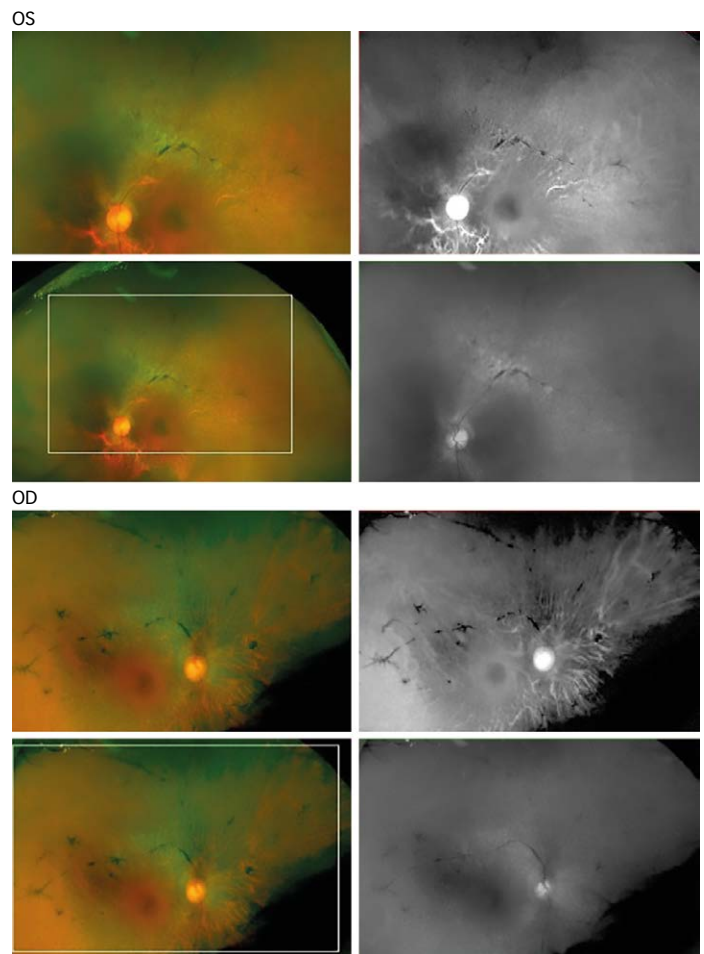


### Relevant capabilities of ultra-widefield retinal imaging for the cataract practice

As occurred with the introduction of OCT, now an essential tool in many cataract practices, UWF retinal imaging is providing new capabilities that are helping to evolve the standard of care. Several platforms for examining the retinal periphery have been developed, including the portable, contact-based RetCam (Natus Medical, Pleasanton, California, US) and contact (Starengi retinal lens—Ocular Instruments, Washington, US) and non-contact lens additions to the Heidelberg Spectralis (Heidelberg Engineering, Heidelberg, Germany), but the Optos systems offer the maximum field of view of any available retinal imaging device.<sup>3</sup> Optos UWF devices are also easier to use and capture images more quickly than other platforms. A single, non-contact capture can show 200-degrees or 82% of the retina, often extending beyond the vortex veins and equator. A number of studies have confirmed that Optos UWF imaging helps clinicians identify pathology associated with a wide array of retinal diseases, including non-infectious uveitis and vasculitis, that can be missed with conventional imaging techniques.<sup>4-6</sup> A review of data from more than 3 years of research with UWF imaging confirmed that that 66% of clinically relevant retinal pathology is found outside the reach of conventional fundus photography.<sup>7</sup>

In our perioperative assessments, the functional capabilities of Optos systems make UWF imaging a useful adjunct to OCT and other standard examination tools, particularly in providing an efficient way to examine the retinal periphery. Each system is built around two low-power lasers and purpose-built optical technology that permit high-resolution image capture through a pupil as small as 2 mm. Since mydriasis is not necessary for excellent visualization, imaging is possible in eyes that cannot be dilated, such as those with anatomic narrow angles, pseudoexfoliation, iris trauma, or uveitis. Considering that many cataract patients are somewhat more light sensitive during the preoperative time period and given the relatively high frequency with which dilated fundus evaluations occur in such patients (for further assessment of dysphotopsias, floaters, visual blur or just routine surveillance), the potential benefits of UWF imaging, including screening sensitivity and efficiency, may be further amplified in this particular group. From the clinician's perspective, conventional retinal imaging can be challenging in patients with cataracts due to light scatter off the cataract. However, the Optos system scanning laser ophthalmoscopy (SLO) technology

Figure 2: Screen shots demonstrating the versatility of optomap in the pre-surgical examination; the color images identified retinitis pigmentosa



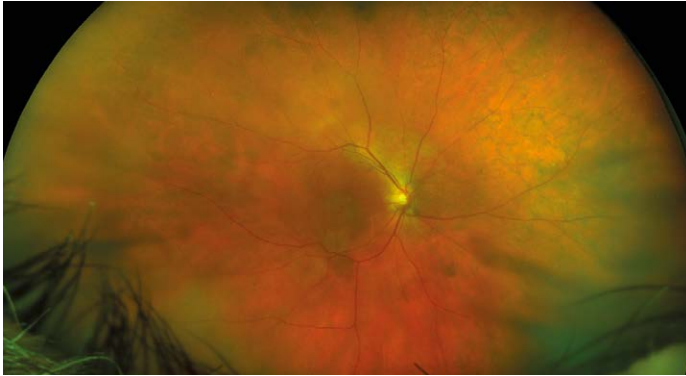Each set of four images (OS/OD) is from a single capture and shows (clockwise from bottom left): 1) original UWF color image; 2) zoomed view of the pathology, note the bone spicule pattern; 3) IR/choroidal view achieved by setting the blend feature to 100% red; 4) red-free/surface view achieved by setting the blend feature to 100% green.

can effectively penetrate most media opacities, allowing adequate visualization through cataracts, vitreous hemorrhages, corneal scars, and gas bubbles or silicone oil (see *Figure 1*).

The sensitivity and clinical value of UWF retinal imaging technology in the identification and assessment of diabetic retinopathy is well documented.<sup>8-11</sup> It has also been evaluated extensively in a spectrum of other retinal diseases, particularly retinal vasculopathies.<sup>12,13</sup> These studies have contributed to the growing significance of peripheral findings to disease management. The ease and speed of optomap image capture makes it feasible to incorporate them into routine exams with the result that overall exam time is reduced and patient satisfaction increased.

Beyond rapid image capture, UWF retinal imaging provides additional efficiency advantages for the cataract practice. The OptosAdvance™ image management software permits cross-registration of multimodal images, the manipulation and annotation of images, and the importation of Digital Imaging and Communications in Medicine (DICOM) compatible images from other diagnostic equipment, all of which can be viewed on

**Figure 3: optomap demonstrating age-related macular degeneration imaged through a cataract allowing visibility of the central atrophy and pigmentary changes in the periphery**



any networked computer screen or tablet. Image storage and sharing between offices or practices is managed through a cloud-based archive, minimizing storage challenges for the individual office. Remote offices are able to review the optomap files over the internet, without the requirement of Optos hardware or software. OptosAdvance also provides a 3D projection of the globe and major anatomical structures, which is very useful in educating patients about the health of their eyes and discussing IOL options.

### The utility of ultra-widefield retinal imaging in the cataract assessment and follow-up

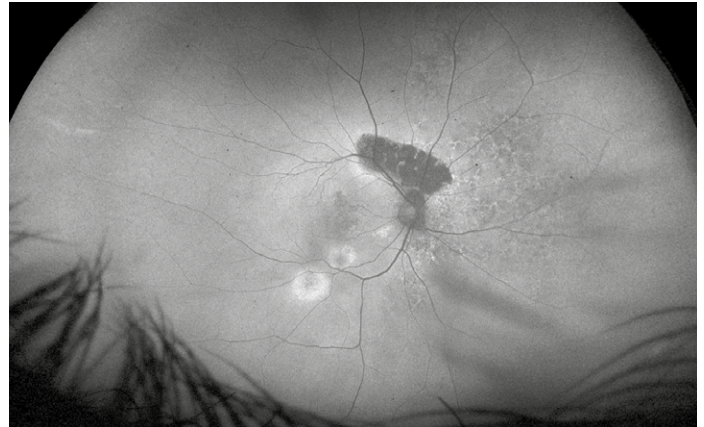#### Pre-existing retinal pathology

Although there are few outright contraindications for cataract surgery, other than a low endothelial cell count, the detection and/or careful evaluation of pre-existing retinal pathology is critical to identify patients who may need treatment of retinal disease prior to cataract surgery or may require particular care during the procedure, both to prevent worsening of the underlying retinal condition and to optimize the outcomes of the cataract procedure. UWF is very useful in identifying and documenting pathologies such as lattice degeneration, macular holes or tears, and cobblestone degeneration, all of which carry a higher risk of retinal detachment.

Cataract evaluation often uncovers the first indications of retinal pathology in a patient, with preoperative referral providing confirmation of a diagnosis. In this case (see *Figure 2*), for example, multimodal UWF imaging revealed retinitis pigmentosa (RP) in a 62-year-old patient referred for blurry vision and cataract. The patient was subsequently seen by a retina specialist and cleared for cataract surgery. Because of the RP diagnosis, we chose a monofocal implant. Following cataract extraction, the patient is 20/30 uncorrected OU and is very happy with his vision. The optomap images were also useful in the process of educating the patient about RP.

In most cases, pre-existing retinal disease, including age-related macular degeneration (AMD) and diabetic retinopathy, does not prevent the patient from undergoing cataract surgery. Large studies have shown that cataract surgery in these patients can provide sustained improvements in visual acuity.<sup>14,15</sup> However, the impact of the procedure on the course of retinal disease remains controversial. Some evidence suggests increases in both the incidence and progression rate of diabetic retinopathy at 1 year after phacoemulsification cataract surgery,

**Figure 4: optomap of image of the same patient illustrates two levels of damage**



*Hypoautofluorescence, a decreased signal, indicates a complete loss of function. Hyperautofluorescence, an increased signal, shows areas of dysfunction, but not loss. The widespread extent of retinal pigmented epithelial damage can be tracked over time.*

and findings are inconsistent from large studies about the association between cataract surgery and long-term risk for the development of either early or late AMD.<sup>16-18</sup> It is clearer that the risk of post-surgical cystoid macular edema is increased in patients with a history of retinal vein occlusion or epiretinal membrane.<sup>19</sup>

Given the totality of the available evidence and our own experience, we are very conservative in the presence of retinal findings and maintain a low threshold for referral to a retina specialist for further evaluation, including a dilated fundus exam and OCT, and potential treatment (see *Figures 3 and 4*). In these situations, the ability to rapidly and easily share an optomap image using the cloud facilitates inter-office communication and efficient patient management. In most of these cases, we are ultimately able to proceed with cataract surgery but may take additional measures in the postoperative phase to monitor the patient and aggressively control inflammation.

#### Lens choice considerations

Pathology in the macula evident on UWF is also important to the consideration of premium lens options, particularly multi-focal IOLs. Because of their design, these lenses can be associated with a decrease in contrast sensitivity and photic phenomena such as glare and halos—effects that can be compounded by retinal disease.<sup>20,21</sup> They may also result in impaired visualization of the retina in subsequent retinal surgery. If evidence of diabetic retinopathy, AMD, or epiretinal membranes is identified on UWF, additional assessment, including macular function, should be conducted in consultation with the retina specialist to help determine the expected course of the disease and the long-term suitability of the lens choice. As lens technology continues to improve, providing greater degrees of spectacle independence with fewer trade-offs in vision quality, and data on long-term performance multi-focal IOLs in the presence of retinal disease is collected, these concerns may eventually be obviated.

#### Postoperative follow-up

While large, prospective studies of the use of UWF in post-cataract monitoring have not yet been performed, Faberowski et al. have demonstrated that non-mydratic color UWF imaging can be used

effectively to screen for retinal pathology in asymptomatic patients following cataract extraction.<sup>22</sup> In their retrospective, observational case series in 76 eyes of 58 consecutive patients, UWF imaging provided good visualization of the peripheral retina in more than 90% of the patients and did not reveal any new retinal tears or detachments, including in patients with prior history of retinal pathology. Another group has demonstrated that non-mydriatic UWF imaging of patients after cataract surgery provides a rate of detection for retinal lesions comparable to mydriatic slit lamp and mydriatic Goldmann three-mirror contact lens examinations, while offering more convenience for the practice and comfort for the patient.<sup>23</sup>

We typically repeat optomap imaging at 2 weeks following surgery, even in asymptomatic patients. This gives us the ability to screen for any fundus changes while obtaining the first baseline UWF image of the retina with the cataractous lens removed.

### Advantages of ultra-widefield retinal imaging in the cataract practice

In our experience, the benefits of integrating UWF retinal imaging into cataract assessment and follow-up can be grouped into five general areas:

#### Standardization

The use of the standardized UWF optomap image, within and between practices, helps reduce inter-observer variability and facilitates diagnostic and management consensus. The ability to overlay different imaging modalities or compare prior images is very useful in detecting and monitoring retinal pathology.

#### Streamlining retinal assessment

The ability to rapidly capture a high-resolution digital image in a patient-friendly manner makes UWF retinal imaging an excellent evaluation tool, obviating the need, time, and cost of a dilated fundus exam unless findings are made. Optomap images can be easily captured by a tech and are immediately available to the surgeon for evaluation.

#### Robust documentation

The standardized, digital optomap image is easily stored, annotated, and compared, providing a clinically useful component of the patient's record. The use of UWF enhances documentation of retinal pathology, cataract opacity, implant choice, and postoperative results.

#### Mapping progression

Evaluation and post-op UWF images create an important baseline for ongoing monitoring of disease progression in patients with evident retinal pathology. The ability to compare a standardized image over time, annotate images, and toggle between imaging modalities provides additional assurance that pathological changes can be identified.

#### Economic advantages

The efficiency and ease of use of UWF imaging potentially allows the evaluation of a larger population of patients over a shorter period of time. For us, this has translated into improved patient flow and surgical volume. In addition, in some cases, documentation of peripheral pathology outside the reach of conventional cameras represents a reimbursable service that improves the economic equation for the practice. Offering UWF retinal imaging on a modest, fee-for-service basis may have similar benefits while ensuring that most patients enjoy the clinical benefits of a baseline optomap.

#### Conclusion

The increasing number of cataract patients—particularly those under 65—and heightened patient expectations about postoperative visual outcomes are placing new demands on the cataract practice's clinical rigor and resource allocation. The integration of Optos UWF retinal imaging into our preoperative assessment and postoperative follow-up protocols is helping to address these issues by offering an efficient, economical, and patient-friendly evaluation tool for retinal pathology, providing a consistent point of reference between clinicians, and helping to document retinal changes over time to help protect the patient's long-term quality of vision. Additional experience by cataract surgeons and evidence from formal studies will help further define the potential contribution of UWF retinal imaging to enhancing immediate and long-term surgical outcomes. □

- Gollogly HE, Hodge DO, St Sauver JL, Erie JC, Increasing incidence of cataract surgery: population-based study, *J Cataract Refract Surg*, 2013;39:1383-9.
- Ortman JM, Velkoff VA, Hogan H, An aging nation: the older population in the United States. Current population reports, May 2014, U.S. Census Bureau.
- Witmer MT, Parlitsis G, Patel S, et al., Comparison of ultra-widefield fluorescein angiography with the Heidelberg Spectralis® noncontact ultra-widefield module versus the Optos® Optomap®, *Clin Ophthalmol*, 2013;7:389-94.
- Leder HA, Campbell JP, Sepah YJ, et al., Ultra-wide-field retinal imaging in the management of non-infectious retinal vasculitis, *J Ophthalmic Inflamm Infect*, 2013;3:30.
- Nicholson BP, Nigam D, Miller D, et al., Comparison of wide-field fluorescein angiography and nine-field montage angiography in uveitis, *Am J Ophthalmol*, 2014;157:673-7.
- Hong BK, Khanamiri HN, Rao NA, Role of ultra-widefield fluorescein angiography in the management of uveitis, *Can J Ophthalmol*, 2013;48:489-93.
- Optos. Data on file.
- Kernt M, Hadi I, Pinter F, et al., Assessment of diabetic retinopathy using nonmydriatic ultra-widefield scanning laser ophthalmoscopy (optomap) compared with ETDRS 7-field stereo photography, *Diabetes Care*, 2012;35:2459-63.
- Silva PS, Cavallerano JD, Sun JK, et al., Nonmydriatic ultrawide field retinal imaging compared with dilated standard 7-field 35-mm photography and retinal specialist examination for evaluation of diabetic retinopathy, *Am J Ophthalmol*, 2012;154:549-59.
- Liegl R, Liegl K, Ceklic L, et al., Nonmydriatic ultra-wide-field scanning laser ophthalmoscopy (optomap) versus two-field fundus photography in diabetic retinopathy, *Ophthalmologica*, 2014;231:31-6.
- Wessel MM, Aaker GD, Parlitsis G, et al., Ultra-wide-field angiography improves the detection and classification of diabetic retinopathy, *Retina*, 2012;32:785-91.
- Tsui I, Franco-Cardenas V, Hubschman J, et al., Ultra wide field fluorescein angiography can detect macular pathology in central retinal vein occlusion, *Ophthalmic Surg Lasers Imaging*, 2012;43:257-62.
- Singer M, Tan CS, Bell D, et al., Area of peripheral retinal nonperfusion and treatment response in branch and central retinal vein occlusion, *Retina*, 2014;34:1736-42.
- Forooghian F, Agron E, Clemons TE, et al., Visual acuity outcomes after cataract surgery in patients with age-related macular degeneration: age-related eye disease study report no. 27, *Ophthalmology*, 2009;116:2093-100.
- Chew EY, Benson WE, Remaley NA, et al., Results after lens extraction in patients with diabetic retinopathy: early treatment diabetic retinopathy study report number 25, *Arch Ophthalmol*, 1999;117:1600-6.
- Hong T, Mitchell P, de Loryn T, et al., Development and progression of diabetic retinopathy 12 months after phacoemulsification cataract surgery, *Ophthalmology*, 2009;116:1510-14.
- Klein BEK, Howard KP, Lee KE, et al., The relationship of cataract and cataract extraction to age-related macular degeneration: the Beaver Dam eye study, *Ophthalmology*, 2012;119:1628-33.
- Cugati S, Mitchell P, Rochtchina E, et al., Cataract surgery and the 10-year incidence of age-related maculopathy: the Blue Mountains eye study, *Ophthalmology*, 2006;113:2020-25.
- Henderson BA, Kim JY, Ament CS, et al., Clinical pseudophakic cystoid macular edema. Risk factors for development and duration after treatment, *J Cataract Refract Surg*, 2007;33:1550-58.
- Braga-Mele R, Chang D, Dewey S, et al., Multifocal intraocular lenses: Relative indications and contraindications for implantation, *J Cataract Refract Surg*, 2014;40:313-22.
- De Vries NE, Nuijts RMMA, Multifocal intraocular lenses in cataract surgery: literature review of benefits and sides effects, *J Cataract Refract Surg*, 2013;39:268-78.
- Faberowski N, Quiroz-Mercado H, Gonzalez C, et al., Retina evaluation with non mydriatic ultra wide field color imaging after cataract surgeries in asymptomatic patients, *Invest Ophthalmol Vis Sci*, 2013;54:2997.
- Peng J, Zhang Q, Jin H-Y, et al., Ultra-wide field imaging system and traditional retinal examinations for screening fundus changes after cataract surgery, *Int J Ophthalmol*, 2016;9:1299-303.





The White House  
Mill Road  
Goring-On-Thames  
RG8 9DD  
UK

T: +44 (0) 207 193 3968  
E: [info@touchmedicalmedia.com](mailto:info@touchmedicalmedia.com)  
[www.touchOPHTHALMOLOGY.com](http://www.touchOPHTHALMOLOGY.com)



[www.touchmedicalmedia.com](http://www.touchmedicalmedia.com)